

## Use of Extracts of *Jatropha Curcas* Leaf Formulated in A Simple Ointment Base in Wound Healing Activities: How Safe Is It?

<sup>1</sup>Nwala, Chukwudi Omeni, <sup>2</sup>Akaninwor, J. O, <sup>3</sup>Monanu, M. O.

<sup>(1)</sup>Department of Biochemistry, University of Port Harcourt, Choba, Port Harcourt, Nigeria.)

<sup>(2)</sup>Department of Biochemistry, University of Port Harcourt, Choba, Port Harcourt, Nigeria.)

<sup>(3)</sup>Department of Biochemistry, University of Port Harcourt, Choba, Port Harcourt, Nigeria.)

---

**ABSTRACT:** The safety of the use of leaf extract of *Jatropha curcas* plant in different groups of wistar albino rats at different doses was investigated. Excision wound of about 21mm diameter size was inflicted on one side of the central trunk of the different groups of the albino rats, and different doses of the leaf extracts formulated into ointments were topically applied on the wound of the different groups for 21 days for wound healing and closure. The animals were sacrificed and the effect of the leaf extract on blood biochemistry and histopathological examination of the kidney and liver tissues were assessed using standard techniques. There were no statistical significant differences ( $p > 0.05$ ) in the result of the biochemical parameters: total protein, albumin, globulin aspartate amino transferase (AST) and alanine amino transferase (ALT), between the control and the experimental animals. Histopathological examination of the kidney and liver tissues showed that the animal had normal histological feature. The findings of this study showed that the leaf extract of *J. curcas* has no harmful effects.

**KEYWORDS:** Biochemical, Histopathological, *Jatropha curcas*, Parameters, Ointment.

---

### I. INTRODUCTION

*Jatropha curcas*, commonly known as physic nut or purging nut, belongs to the Euphorbiaceae family. It is a multi-purpose tree and of significant economic importance. It grows quickly; survives in poor stony soils; is resistant to drought and diseases, and reaches the height of about 3-8m, and can be grown in waste lands [1]. The plant can easily be propagated by cutting or direct seeding, and is widely planted as hedge to protect fields since it is not browsed by cattle or other animals [2]. The physic nut (*J. curcas*) is a drought resistant species which is widely cultivated in the tropics as a living fence. Many parts of the plant are used in traditional medicine. The seeds, however, are toxic to humans and animals [3]. Traditionally, herbs have been considered to be non-toxic and have been used for treating various problems by the general public and/or herbalists worldwide [4]. Documented severe toxicity resulting from the use of herbs on many occasions abounds, yet the potential toxicity of herbs has not been recognized by the general public or professional groups of traditional medicine practitioners [5]. Patients are often unaware of important similarities and differences between medicinal herbs and approved medications. Some mistakenly think of herbs as natural alternative to chemicals, failing to recognize that herbs are composed of bioactive chemicals, some of which may be toxic [6].

The rural people of Igbo in Etche Local Government Area of Rivers State, Nigeria use the extract of the leaves of *J. curcas* in the treatment of wound as well as a haemostatic agent without due consideration for its safety. The extract from the leaves are usually applied on the wound and the bleeding skin before its action is felt, and it may get into the body system and cause some adverse reactions, if it possesses any poisonous phytochemical. The therapeutic effect of the extracts of *J. curcas* leaves has been documented [7], but its safety remains unknown even though no known adverse effects among the users has been observed. The present study is therefore designed to examine the histopathology of the liver and kidneys tissues of rats treated with the extracts of *J. curcas*, using some biochemical parameters, with a view to assessing the safety status the extracts.

### II. MATERIALS AND METHODS

#### 2.1. Plant Materials

The *Jatropha curcas* leaves (fig. 1, below), used for the work were obtained from Igbo in Etche Local Government Area of Rivers States, Nigeria, where the plant is normally used as life tree to make fence that demarcate plots of land. The leaves were sun-dried and pulverized and stored in an air-tight container for further use. About 250g of the pulverized leaf sample was extracted with methanol [8]. The extract was filtered using Whatman's No. 1 filter paper and the filtrate was concentrated to dryness in vacuo using a rotary evaporator to remove the methanol.



**Figure 1: *Jatropha curcas* plant**

## 2.2 Experimental Animals

Thirty (30) wistar albino rats (of mass between 180 and 250g), obtained from the animal house of Department of Biochemistry, University of Port Harcourt, were divided into five groups where each group has 6 animals (n=6) for the study. The rats were allowed to acclimatize in the research laboratory for 5 days before the commencement of the study. The rats were fed with standard feed (Guinea feed Nigeria Ltd), and allowed unrestricted access to clean drinking water.

## 2.3 Preparation Of *J. Curcas* Extract Ointments

The formulated ointments of *J. curcas* were prepared as described by Esimone *et. al.*, [8]. Five batches of the prepared ointments were used for the study. Batches 1-3 contained three different extracts (each of varying the concentrations: 0.5, 1.0 and 1.5g per 10g of the ointment base, respectively). Batch 4 was the commercial gentamycin ointment, gentalek cream®, containing 1.0% gentamycin and was used as a standard drug treatment. Batch 5 was a blank ointment (control) and was prepared with neither the extract nor the standard drug. For each batch, 10.0g of blank petroleum jelly B.P was weighed into a beaker and then melted in a thermostatic water bath. The required quantity of the extract was weighed, added to the molten ointment base and then homogenized by trituration.

## 2.4 Wound Healing Studies

A round seal of 21mm diameter was impressed on one side of the central trunk depilated and sterilized with ethanol. Excision wound was inflicted on the rats according to the methods described by Esimone *et al.*, [8] under light ether anaesthesia. The rats were treated accordingly using the different ointments. At the end of the experiments, the rats were sacrificed and the effects of treatment with extracts of *J. curcas* leaves on blood biochemistry and histopathological examination assessed.

## 2.5 Determination Of Serum Biochemical Parameters

Total protein was measured using biuret reagent while albumin was measured by colorimetric estimation, using the Sigma diagnostics albumin reagent (Sigma diagnostic, U.K), which contained bromocresol green (BCG). Globulin was obtained from the difference between total protein and albumin. Aspartate amino transferase (AST) and alanine amino transferase (ALT) were also measured. AST was determined by monitoring the concentration of oxaloacetate hydrazone formed with 2,4-dinitrophenyl hydrazine and ALT by monitoring the concentration of pyruvate hydrazone formed with 2,4-dinitrophenyl hydrazine [9].

## 2.6 Histopathological Evaluation

The animals (Wistar albino rats) used for the study were finally sacrificed and the effect of the extract of *J. curcas* leaves on the organs, (Kidney and Liver) examined as described by Arhoghro *et. al.*, [10].

## 2.7 Statistical Analysis

The data were analyzed using tables, range, means, percentages, standard deviation and hence standard error (SE). Also all the data obtained were subjected to analysis of variance (ANOVA) using computer-aided science planning and scheduling system (SPSS) programme, and the means separated and compared using Duncan's multiple range test [11] at 5% level of significance.

# III. RESULTS

## 3.1 BIOCHEMICAL PARAMETERS

The total protein of the blank ointment-treated group was significantly higher ( $p < 0.05$ ) than that of the other treatment groups. The albumin levels ranged from  $35.23 \pm 0.26$ g/dl (0.5/10g ointment base treated group) to  $43.07 \pm 0.43$ g/dl (gentamycin ointment treated group). The albumin levels of the blank ointment-treated group

(37.2 ± 0.13g/dl) was significantly different ( $p < 0.05$ ) from the rest groups. The gentamycin ointment treated group had globulin levels (6.10 ± 0.16g/dl) that was significantly ( $p < 0.05$ ) reduced, relative to the groups treated with 0.5g/10g (10.07 ± 0.18/dl), 1.0g/10g (7.37 ± 0.20g/dl) and blank (9.67 ± 0.20g/dl) ointments. The observed AST levels of the rats were 88.33 ± 0.67 μ/l (for the 1.0/10g ointment), 77.00 ± 1.00 μ/l (for the 1.5g/10g ointment), 76.83 ± 0.19 μ/l (for gentamycin ointment) and 76.67 ± 0.32 μ/l (for the blank ointment). The ALT levels was none significantly ( $p > 0.05$ ) higher in the group treated with 1.0g/10g ointment, relative to the rest treatment groups. The above result is presented in table 1 below.

**Table 1: Results Of Biochemical Parameters Used To Evaluate The Effect Of Treatment With Extract of *Jathopa Curcas* Leaf Based Ointment (at Different Dose Levels) on Excision Wound Healing In Rats.**

Groups	Total Protein g/l	Albumin g/dl	Globulin g/dl	AST μ/l	ALT μ/l
0.5g/10g of ointment-base.	49.10 ± 0.16 <sup>acd</sup>	35.23 ± 0.26 <sup>a</sup>	10.07 ± 0.18 <sup>ae</sup>	88.33 ± 0.67 <sup>ab</sup>	17.60 ± 0.35 <sup>a</sup>
1.0g/10g of ointment-base.	44.80 ± 0.46 <sup>b</sup>	42.97 ± 0.56 <sup>bcd</sup>	7.37 ± 0.21 <sup>bc</sup>	88.00 ± 0.58 <sup>ab</sup>	18.10 ± 0.52 <sup>a</sup>
1.5g/10g of ointment-base.	48.03 ± 0.43 <sup>acd</sup>	42.07 ± 0.24 <sup>bcd</sup>	6.50 ± 0.32 <sup>bcd</sup>	77.00 ± 1.0 <sup>cd</sup>	17.33 ± 0.46 <sup>a</sup>
Gentamycin	48.23 ± 0.14 <sup>acd</sup>	43.07 ± 0.43 <sup>bcd</sup>	6.10 ± 0.16 <sup>cd</sup>	76.83 ± 0.19 <sup>cd</sup>	17.95 ± 0.55 <sup>a</sup>
Blank ointment	51.07 ± 0.18 <sup>e</sup>	37.23 ± 0.13 <sup>a</sup>	9.67 ± 0.20 <sup>ae</sup>	76.67 ± 0.32 <sup>cd</sup>	17.33 ± 0.88 <sup>a</sup>

Values are means ± standard deviation of triplicate determinations.

Means in the same column with different superscript letters were significantly different at the 0.05 level.

### 3.2 Histological Examination of Effect (Safety) of *Jatropha Curcas* Leaf Extract Based-Ointment on Excision Wound Healing In Rats.

All the kidney and liver tissues of the groups treated with 0.5g/10g ointment base had normal histologic features. The group treated with 1.0g/10g ointment base had kidney tissues with normal histology, while the liver tissues had mild balloon degeneration. The 1.5g/10g ointment base treated-group had kidney tissues that presented normal histology, while the liver tissues showed balloon degeneration.


The group treated with gentamycin ointment had kidney and liver tissues with normal histologic features. The group treated with blank ointment also had kidney and liver tissues that presented normal histologic features. This result is presented in table 2 below.

**Table 2: Results of Histological Examination of Effect (Safety) of *Jatropha Curcas* Leaf Extract Based Ointment On Excision Wound Healing in Rats**

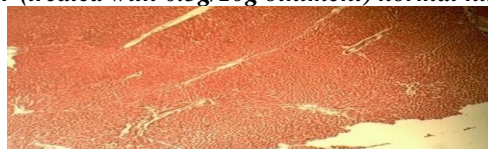
TISSUE SLIDE	TREATMENT GROUPS	DESCRIPTION OF HISTOLOGICAL EXAMINATION
	<u>0.5g/10g ointment</u>	
Kidney	→	Normal histologic features.
Liver	→	Normal histologic features.
	<u>1.0g/10g ointment</u>	
Kidney	→	Normal histology.
Liver	→	Mild balloon degeneration.
	<u>1.5g/10g ointment</u>	
Kidney	→	Normal histology.
Liver	→	Balloon degeneration.
	<u>Gentamycin ointment</u>	
Kidney	→	Normal histologic features.
Liver	→	Normal histologic features.
	<u>Blank ointment</u>	
Kidney	→	Normal histologic features.
Liver	→	Normal histologic features.

The photomicrographs (plates 1-10) below represent the kidney and liver tissues of the five (5) different treatment groups of the leaf extracts of *J. curcas*.

**PLATE 1: Kidney (treated with 0.5g/10g ointment) normal histologic features**

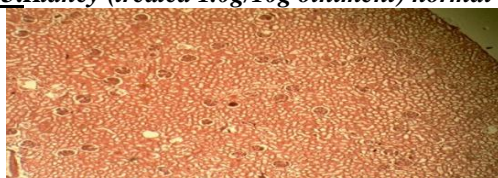


**PLATE 2: Liver (treated with 0.5g/10g ointment) normal histologic features.**

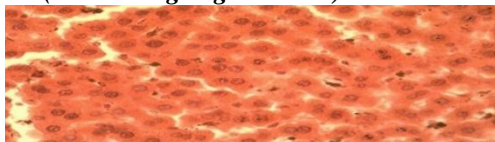




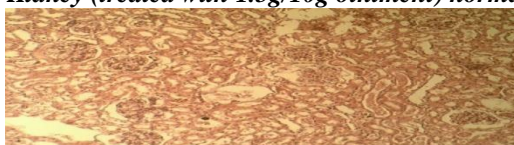**PLATE 3:** *Kidney (treated 1.0g/10g ointment) normal histology.*



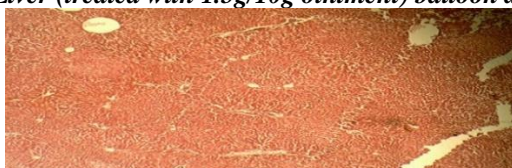
**PLATE 4:** *Liver (treated 1.0g/10g ointment) mild balloon degeneration.*



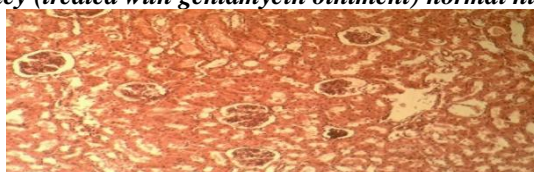**PLATE 5:** *Kidney (treated with 1.5g/10g ointment) normal histology.*



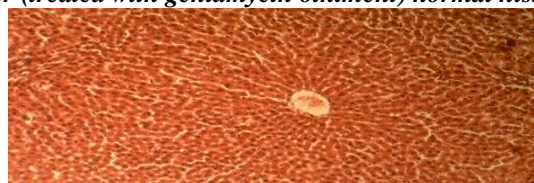
**PLATE 6:** *Liver (treated with 1.5g/10g ointment) balloon degeneration.*



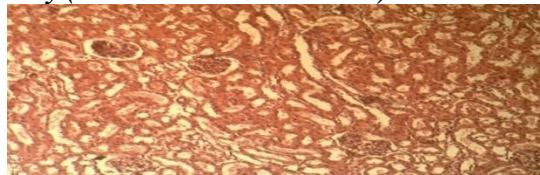
**PLATE 7:** *Kidney (treated with gentamycin ointment) normal histologic features.*



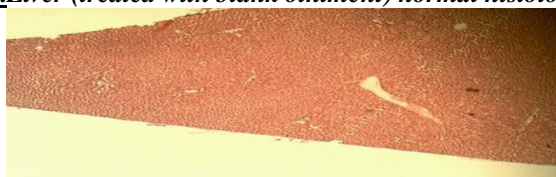
**PLATE 8:** *Liver (treated with gentamycin ointment) normal histologic features.*



**PLATE 9:** *Kidney (treated with blank ointment) normal histologic features.*



**PLATE 10:** *Liver (treated with blank ointment) normal histologic features.*



#### IV. DISCUSSION

Most rural dwellers of Igbo in Etche Local Government of Rivers State, Nigeria, use the leaf extracts of *J. curcas* for wound treatment without safety considerations. Its efficacy in wound treatment has been established [7], [8]. Although there has been no known adverse reaction to the leaf extracts of *J. curcas* on the users, data on its safety record is not available. From the present study, the leaf extracts of *J. curcas* had total protein that was best in the blank ointment treated-group (control) when compared to the other treatment groups. The various treatment groups had albumin contents that were highest in the group treated with standard drug, gentamycin. The albumin levels were also higher when compared with the control (blank ointment) group, while the globulin contents were lower than that of the control. These results were similar to the ones reported by Oyedapo [12], Adeoye and Oyedapo [13]. The levels of total proteins, albumin and globulin contents observed in these treatments were very little and of no significant import. These invariably mean that topical treatment of the rats with the ointments formulated from the extracts of these samples on excision wound had no adverse effect on the rats. The liver is the principal organ involved in bio-transformation of exogenous substances, and therefore is involved in a lot of enzyme synthesis that enable it to carry out its function. Liver enzymes are usually raised in acute hepatotoxicity but tend to decrease with prolonged toxication due to damage to the liver cells [14]. The AST and ALT levels of the rats were a little higher when compared to the level of the control group, though, the levels were not significantly different ( $p>0.05$ ) from each other. This showed that there were no noticeable changes in the ALT levels of the experimental animals as a result of the treatment. The levels of these enzymes were lower than the ones reported by Arhoghro *et al.*, [10].

Histopathological examination of the kidney and liver cells of the rats showed that the kidneys of the rats in all the treatment groups had normal histological features. The liver tissues for all the treatment groups also showed normal histologic features, apart from that of the groups treated with 1.0/10g and 1.5g/10g ointment base that had mild balloon degeneration. This is an indication that the topical treatment of the rats with the leaf extracts of *J. curcas* formulated ointments did not cause harm to the rats, which also corroborated the report of Ojiako and Nwanjo [[15].

#### V. CONCLUSION

The *J. curcas* leaf extracts formulated ointments have no adverse effect on the experimental animals. This observation is in agreement with the belief of users of this plant that the plant is safe. The finding of this study can be extrapolated to humans since the use of the leaf extracts in wound healing in rats was safe.

#### REFERENCES

- [1] J. Martinez-Herrera, P. Siddhuraju, G. Francis, G. Davila-Ortiz, K. Becker. Chemical Composition, Toxic/Antimetabolic Constituents, and Effects of Different Treatments on their levels, in four Provenances of *Jatropha Curcas* L. from Mexico. *Food Chemistry*.96, 2006, 80-89.
- [2] J. Heller. Physic nut (*J. curcas* L.). Promoting the conservation and use of und-utilized and neglected crops. I. Gatersleben: Institute of Plant Genetics and Crop Plant Research/Rome: International Plant Genetic Resources Institute, 1996.
- [3] D. Juo-Long, Clinical toxicity of herbal medicine in Taiwan. 7<sup>th</sup> International Conference on Health problems related to the Chinese, 1994.
- [4] T. Oduola, G. B. Popoola, O. G. Avwioro, T. A. Oduola, A. A. Ademosun and M. O. Lawal. Use of *Jatropha gossypifoliastem* latex as a haemostatic agent: How safe is it. *J. of Med. Plant Research*. 1(1), 2007, 014-017.
- [5] M. O' Hara, D. Kiefer, K. Farrel, and K. Kemper. A Review of 12 commonly used medicinal Herbs. *Arch. Fam. Med.*, 1998, 523-536.
- [6] [6] V. E. Tyler. Herbs of choice. The therapeutic use of phytomedicinals. Binghamton, N. Y: Harworth Press Inc., 1994. .Pp 23-27
- [7] C. O. Nwala. Nutritional, Toxicological and Pharmacological Evaluation of *Jatropha curcas* plant, doctoral diss., University of Port Harcourt, Nigeria, PhD, 2013.
- [8] C. O. Esimone, C. S. Nworu and C. L. Jackson. Cutaneous Wound Healing Activity of a Herbal Ointment Containing the Leaf Extract of *J. Curcas* L. (Euphorbiaceae). *Int'l. Journal of Applied Research in Natural Products*. 1(4), 2009, 1-4.
- [9] A. A. Adedapo, M. O. Abatan and O. O. Olorunsogo. Toxic Effects of Some Plants in the Genus Euphorbia on Haematological and Biochemical Parameters of Rats. *Vet. Arhiv*.74, 2004,53-62.
- [10] E. M. Arhoghro, K. E. Ekpo, E. O. Anosike and G. O. Ibeh. Effect of Aqueous Extract of Bitter Leaf (*Vernonia amygdalina* Del) on Carbon Tetrachloride (CCl<sub>4</sub>) Induced Liver Damage in Wistar Albino Rats. *Euro. J. of Sci. Research*, 26, 2009, 122-130.
- [11] D. B. Duncan. Multiple Range and Multiple F. Tests, *Biometrics*.11, 1955, 1-42.
- [12] O. O. Oyedapo. Biological Activities of *Phyllanthus amarus* Extracts on Sprague Dawley Rats. *Nig. J. Biochem. Molec. Biol*.16, 2001, 83-86.
- [13] B. A. Adeoye and O. O. Oyedapo. Toxicity of *Erythrophleum guineense* stem-bark: Role of alkaloidal fraction. *African Journal of Traditional Complementary Alternative Medicines* 1(1), 2004, 45-54.
- [14] C. E. Cornelius. Serum Enzyme Activities and other Markers for Detecting Hepatic Necrosis, Cholestasis or Cocarcinoma. In: *Clinical Biochemistry of Domestic Animals*. 4<sup>th</sup> ed. Academy Press, 1989, Pp. 381-386.
- [15] O. H. Ojiako and H. U. Nwanjo. Is *Vernonia amygdalina* Hepatotoxic or Hepatoprotective? Response from Biochemical and Toxicity Studies in Rats. *Afr. J. Biotechnol*, 5(18), 2006, 1648-1651.